Mass Veterinary Services

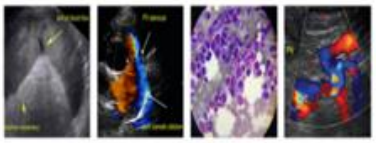

SonoPath
Clinical Sonography & Telecytology
EDUCATIONAL TELECONSULTATION SERVICES™
1-800-838-4268 info@sonopath.com SonoPath.com

PATIENT
Theo Kelley

SPECIES
Feline

BREED
DSH

SEX
Male Neutered

AGE
8 years

WEIGHT
13.3lbs

INTERPRETED BY
Maggie Machen Lamy, DVM DACVIM (Cardiology)

IMAGING PERFORMED BY
Pamela Harrigan, RDCS

HOSPITAL NAME
Mass Veterinary Services

REFERRING VET
Dr. Masloski

INVOICE
30024

DATE
4/4/23

PRESENTING CLINICAL SIGNS

History: Recheck echo. History overtly normal cardiac structure and function with mild LAE and LV remodeling on prior echocardiogram (8/31/22 MML). Presently, Theo is doing well at home with no concerns. He eats well with normal activity. On exam: NSR, grade II/VI parasternal murmur, PSS, lung fields clear, compressible thorax, mm pink, moist, CRT<2. BP: 130 mmHg x 3.
-Pertinent previous echo measurements (8/2022 MML): LA 1.5 cm; LA:Ao 1.5; LV 1.6 cm; IVS 0.42 cm; PW 0.50 cm

ECHOCARDIOGRAM FINDINGS

2D, m-mode, color flow and Doppler imaging is available.
Left ventricle: The LV diameter is normal with adequate myocardial function. The LV wall thicknesses are normal. There is a diffusely hyperechoic endocardium consistent with mild fibrosis. False tendon. The endocardium appears mildly remodeled. The papillary muscles are mildly remodeled and hyperechoic.
Left atrium: The left atrium is mildly increased in size. No obvious spontaneous contrast or thrombi seen.
Mitral valve: The mitral valve is normal in structure and mobility. Trace MR. No obvious systolic anterior motion is seen.
Aortic valve/aorta: The aortic valve is normal in morphology and mobility. Normal aortic outflow velocity; laminar flow. No aortic insufficiency.
Right ventricle: Normal right ventricular diameter and morphology indicating no overt evidence of pulmonary arterial hypertension.
Right atrium: The right atrium is normal in dimension.
Tricuspid valve: The tricuspid valve appears normal with trace tricuspid regurgitation.
Pulmonic valve/pulmonary artery: The pulmonic valve is normal in morphology and mobility. No pulmonic insufficiency. Normal RVOT velocity; laminar flow.
Pericardium/other: No pericardial or pleural effusion noted. No obvious cardiac masses.
Heart rhythm: ECG reveals a sinus rhythm with an average HR of 170bpm.

2-Dimensional Measurements

Ao diam (cm)	0.9
LA diam (cm)	1.4
LA:Ao (Swe)	1.5
IVS thickness (cm)	0.49
LVID diastole (cm)	1.4
PW thickness (cm)	0.53
LVID systole (cm)	0.7
FS (%)	50

Doppler Measurements

PV Vmax (m/s)	0.8
AoV Vmax (m/s)	1.2
MR Vmax (m/s)	NA
TR Vmax (m/s)	NA
TR PG (mmHg)	NA

INTERPRETATION OF THE FINDINGS

Compared to the prior study, findings are similar. Mild remodeling and fibrosis is unchanged without progressive LV hypertrophy. The LA remains mildly enlarged, although no significant change is appreciated. No cause for the murmur remains apparent in this exam. While the included ECG is unremarkable, isolated APCs were captured during the study. An extended tracing may be warranted if the abnormality is detected on serial exams.

Mass Veterinary Services

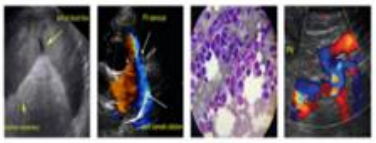

SonoPath
Clinical Sonography & Telecytology
EDUCATIONAL TELECONSULTATION SERVICES™
1-800-838-4268 info@sonopath.com SonoPath.com

PATIENT
Theo Kelley

SPECIES
Feline

BREED
DSH

SEX
Male Neutered

AGE
8 years

WEIGHT
13.3lbs

INTERPRETED BY
Maggie Machen Lamy, DVM DACVIM (Cardiology)

IMAGING PERFORMED BY
Pamela Harrigan, RDCS

HOSPITAL NAME
Mass Veterinary Services

REFERRING VET
Dr. Masloski

INVOICE
30024

DATE
4/4/23

RECOMMENDATIONS

- Given these findings, no medications are indicated.
- The risk for general anesthesia is low, however heart rate stimulating drugs such as atropine, glycopyrrolate, etc. should be avoided unless medically necessary. With mild LA dilation there may be an elevated risk for fluid overload in this patient and judicious IV fluid use is recommended.
- Monitor for any clinical evidence of cardiac compromise, including respiratory changes and/or signs of a blood clot event (paralysis, neurologic changes, etc.

PLAN

- Recommend recheck echocardiogram in 6-12 months to reassess murmur origin and screen for progressive LA dilation.

IMAGES

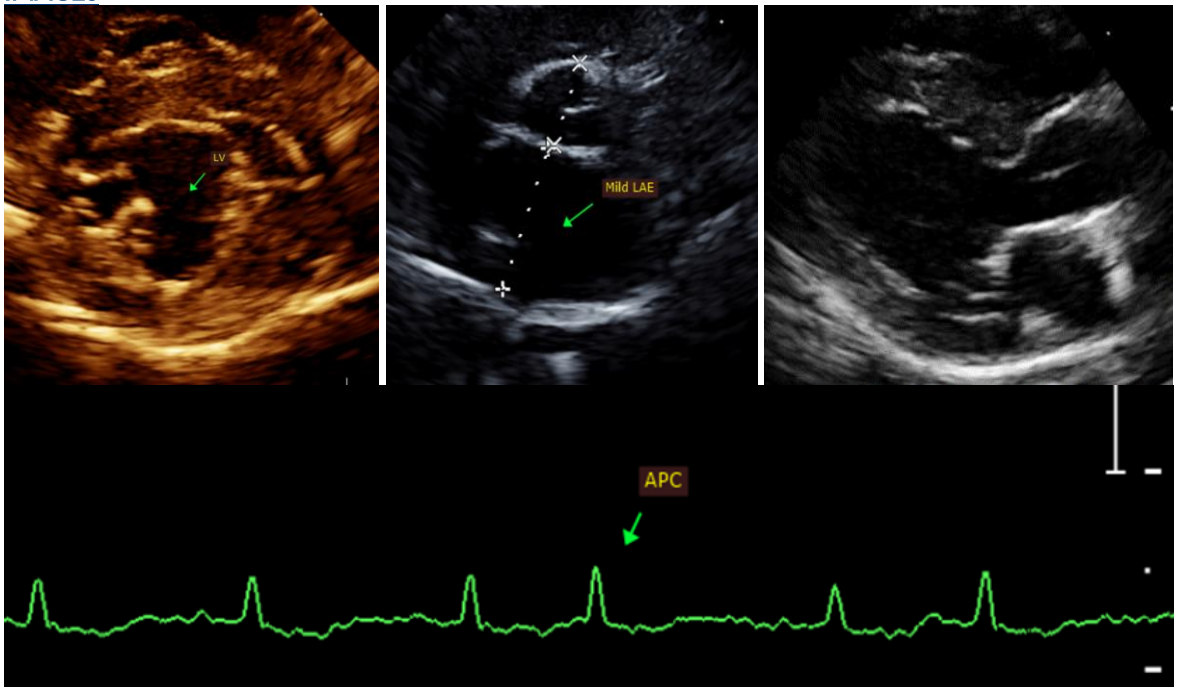

The information and recommendations provided are based on the images presented by the referring veterinarian. No evaluation can be communicated regarding pathology that was not visible in the image/video clips provided.

Thank you for this referral. This report was generated using transcription software, and minor dictation errors may be present. If the clinical or image interpretation does not parallel your findings or if I can be of any further assistance, please contact me.

Maggie Machen Lamy, DVM
Diplomate of the American College of Veterinary Internal Medicine (Cardiology)
info@sonopath.com

Echocardiogram performed by: Pamela Harrigan, RDCS

Mass Veterinary Services

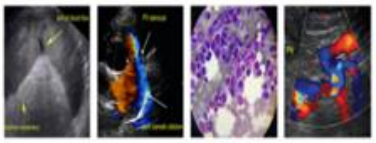

SonoPath
Clinical Sonography & Telecytology
EDUCATIONAL TELECONSULTATION SERVICES™
1-800-838-4268 info@sonopath.com SonoPath.com

Pet Animal Ultrasound Service (4paus.com)

PATIENT
Theo Kelley

SPECIES
Feline

BREED
DSH

SEX
Male Neutered

AGE
8 years

WEIGHT
13.3lbs

INTERPRETED BY
Maggie Machen Lamy, DVM DACVIM (Cardiology)

IMAGING PERFORMED BY
Pamela Harrigan, RDCS

HOSPITAL NAME
Mass Veterinary Services

REFERRING VET
Dr. Masloski

INVOICE
30024

DATE
4/4/23